



**PATIENT**  
Velvet Here Today  
Sanctuary

**SPECIES**  
Feline

**BREED**  
DSH

**SEX**  
Female Spayed

**AGE**  
1.8 years

**WEIGHT**  
7.4lbs

**INTERPRETED BY**  
Maggie Machen  
Lamy, DVM  
DACVIM (Cardiology)

**IMAGING PERFORMED BY**  
Pamela Harrigan,  
RDCS

**HOSPITAL NAME**  
Mass Veterinary  
Services

**REFERRING VET**  
Dr. Masloski

**INVOICE**  
31416

**DATE**  
6/19/23

**PRESENTING CLINICAL SIGNS**

History: Recheck echo. History perimembraneous VSD noted on previous echo 5/10/22 (MML). Presently, Velvet is doing well with a good appetite and normal activity level. On exam: NSR, grade IV/VI parasternal murmur, PSS, lung fields clear, compressible thorax, mm pink, moist, CRT<2. BP: 100-110mmHg. Currently, no medications. \*Sedated with propofol for study.

-Pertinent previous echo findings: LA 1.4 cm; LA:Ao 1.55; lv 1.6 cm, IVS 0.35 cm; PW 0.35 cm, mild LAE, normal LV size, perimembraneous VSD with left to right shunt (5.7 m/s) -Pertinent previous echo findings: LA 1.4 cm; LA:Ao 1.55; LV 1.6 cm, LVS 0.35 cm; PW 0.35 cm.

**ECHOCARDIOGRAM FINDINGS**

2D, m-mode, color flow and Doppler imaging is available.

**Left ventricle:** The LV diameter is normal in dimension with adequate myocardial function. LV wall thicknesses are normal. The papillary muscles remodeled. False tendon. A restrictive perimembraneous ventricular septal defect (VSD) is visualized; 0.2cm in diameter. The flow is left to right and high velocity (4.6m/s).

**Left atrium:** The left atrium is mildly enlarged.

**Mitral valve:** The MV appears normal. No MR.

**Aortic valve/aorta:** The aortic valve is normal in morphology and mobility. Normal aortic outflow velocity; laminar flow. No aortic insufficiency.

**Right ventricle:** The RV appears normal with no evidence of hypertrophy.

**Right atrium:** Normal RA dimension.

**Tricuspid valve:** The tricuspid valve appears mildly thickened. The septal leaflet appears associated with the defect with mild tricuspid regurgitation. Normal velocity.

**Pulmonic valve/pulmonary artery:** The pulmonic valve is normal in morphology and mobility. No pulmonic insufficiency. Normal RVOT velocity; laminar flow.

**Pericardium/other:** No pericardial or pleural effusion noted. No obvious cardiac masses.

**2-Dimensional Measurements**

Ao diam (cm)	0.8
LA diam (cm)	1.4
LA:Ao (Swe)	0.7
IVS thickness (cm)	0.38
LVID diastole (cm)	1.4
PW thickness (cm)	0.36
LVID systole (cm)	1.0
FS (%)	33

**Doppler Measurements**

PV Vmax (m/s)	0.5
AoV Vmax (m/s)	0.85
MR Vmax (m/s)	NA
TR Vmax (m/s)	2.1
TR PG (mmHg)	17

**INTERPRETATION OF THE FINDINGS**

Compared to the prior study, findings are similar. The VSD is readily apparent with left to right flow. Of some concern, the max velocity is slightly decreased; however, given a lack of right or left heart enlargement, this may reflect a normal variant. Monitoring is certainly recommended. Mild LA enlargement is unchanged, in addition to mild TR. No additional issues are identified.

Given these findings, no medications are indicated. Serial monitoring is recommended.

Prognosis is open long-term.

**RECOMMENDATIONS**

- No medications are indicated.



**PATIENT**  
Velvet Here Today  
Sanctuary

- Omega fatty acid supplementation and mild salt restriction may be of some long-term benefit.
- No cardiac contraindication for general anesthesia. Mild IV fluid restriction is advised.
- Monitor for any breathing change, signs of a blood clot event, or collapse episodes going forward.

**SPECIES**  
Feline

**PLAN**

- Recommend conservative monitoring with a recheck echocardiogram annually, sooner if any development of clinical signs.

**BREED**  
DSH

**IMAGES**

**SEX**

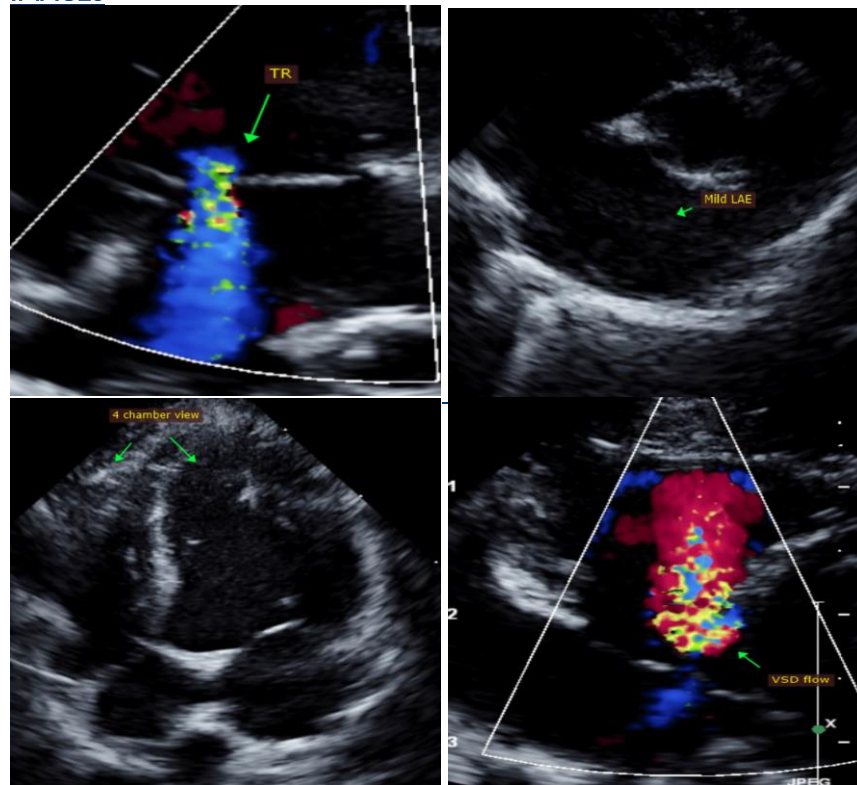
Female Spayed

**AGE**

1.8 years

**WEIGHT**

7.4lbs



**INTERPRETED BY**

Maggie Machen  
Lamy, DVM  
DACVIM (Cardiology)

**IMAGING  
PERFORMED BY**

Pamela Harrigan,  
RDCS

**HOSPITAL NAME**

Mass Veterinary  
Services

The information and recommendations provided are based on the images presented by the referring veterinarian. No evaluation can be communicated regarding pathology that was not visible in the image/video clips provided.

**REFERRING VET**

Dr. Masloski

Thank you for this referral. This report was generated using transcription software, and minor dictation errors may be present. If the clinical or image interpretation does not parallel your findings or if I can be of any further assistance, please contact me.

**INVOICE**

31416

Maggie Machen Lamy, DVM  
Diplomate of the American College of Veterinary Internal Medicine (Cardiology)  
info@sonopath.com

**DATE**

6/19/23

Echocardiogram performed by:

Pamela Harrigan, RDCS  
Pet Animal Ultrasound Service (4paus.com)